

Oligoasthenoteratozoospermia After Trial of Testicular Salvaging Surgery in Testicular Torsion: A Case Report

Muhammad Ainul Mahfuz^{1*}, Suwanto¹, Muhammad Sidharta Krisna²

¹Department of Surgery, Hikmah Masamba Hospital, North Luwu, South Sulawesi, Indonesia

²Department of Urology, Megabuana Hospital, Palopo, South Sulawesi, Indonesia

*Corresponding Author. E-mail: ainulmahfuz@yahoo.co.id, Mobile number: +6285299187147

ABSTRACT

Testicular torsion (TT) is an emergency in urology that happens because of the spermatic cord's rotation. Decreased of overall sperm parameters after TT often happens in which can endanger the patient's fertility status. Approach on how to salvage the testicle and to prevent unwanted complications remains as the doctor's greatest priority. We report a case of oligoasthenoteratozoospermia after surgical detorsion without orchidectomy in testicular torsion. A 19-year-old male, presenting with sudden, progressive, and continuous pain in the right testicle for 4 hours. The right testicle was larger in volume on physical examination, there were a negative phren sign and negative cremasteric reflex. Gray scale ultrasound without Doppler showed changes suggestive of testicular torsion. Emergency surgery revealed a dark-bluish right testicle with a 360° rotation of the spermatic cord. Detorsion without orchidectomy was performed with clinical judgment hoping for the restoration of testicular viability. Sperm analysis was done after one month and oligoasthenoteratozoospermia was found. Although some patients experience decreased overall sperm parameters after TT that perhaps making them infertile, interestingly there is no difference in pregnancy rates among couples with TT men when compared to the general population. The best testicular salvage surgery method to prevent testicular atrophy also has not been determined yet. Thus, the patient should be carefully counseled about the good outcome of pregnancy rate and the chance for testicular atrophy, regardless of what is the surgical choice.

Keywords: Spermatic cord torsion; oligospermia; asthenozoospermia; infertility; male

Article history:

Received: 11 October 2020

Accepted: 21 December 2020

Published: 30 December 2020



GREEN MEDICAL
JOURNAL
E-ISSN 2686-6668

Published by :

Faculty of Medicine
Universitas Muslim Indonesia

Mobile number:

+62822 9333 0002

Address:

Jl. Urip Sumoharjo Km. 5, Makassar
South Sulawesi, Indonesia

Email:

greenmedicaljournal@umi.ac.id

Introduction

Testicular torsion (TT) is an emergency in urology that affects 1 in 4,000 males aged <25 years and happens because of the rotation of the spermatic cord. TT usually happens without any clear cause, but it has been linked with anatomical, traumatic, and environmental factors, among others.^{1, 2, 3} TT causes an arterial constriction in which will develop ischemia causing injury to the testicle tissue, which is why it must be treated with immediate surgery.¹ Diagnosis of TT based mainly on presenting symptoms and signs together with scrotal ultrasonography which is considered the single most useful examination in the diagnosis of torsion. Once the diagnosis is confirmed, immediate surgical exploration is mandatory for detorsion and either orchiopexy or orchiectomy depends upon the viability of testis.⁴

Males were considered infertile if sperm parameters below the World Health Organization (WHO) standard value. This is possibly due to decreased sperm count (oligozoospermia), decreased sperm motility (asthenozoospermia), abnormal sperm morphology (teratozoospermia), or any combination of these.⁵ All three anomalies often occur simultaneously, called oligoasthenoteratozoospermia (OAT) syndrome.⁶ Infertility is majority caused by an intrinsic testicular disorder. TT contributes to male infertility accounting for 5.8% of causes of testicular insufficiency.⁷

There is conflicting evidence as to how the torted testis should be surgically treated. Remove or leave the testis in the scrotum after detorsion is still becoming the big question and both seem to have a devastating influence on testicular function, probably indicating the bilateral damage caused by torsion or there is inadequate capacity in the contralateral testis to increase spermatogenesis and testosterone production. Because of the contradiction about the management, we tried one of the treatment choices for testicular torsion patient in our hospital to see the result of the treatment and report it in this case report. We report in this article a case of oligoasthenoteratozoospermia after surgical detorsion without orchidectomy in testicular torsion.

Case

A 19-year-old male was admitted to the Emergency Room of the Hikmah Masamba Hospital of North Luwu, presenting with a sudden and continuous pain in the right testicle for 4 hours. The pain was progressive, radiated to the right inguinal area, and accompanied by nausea and vomiting. There is no previous history of trauma, fever, irritative voiding symptoms, similar symptoms, or similar problems in the family. The right testicle was found to be larger in volume than the left one on physical examination. It was painful there was a negative phren sign also an absence of the cremasteric reflex. The left testicle was normal. Laboratorium tests were only showed leukocytosis. Gray scale ultrasound without Doppler was done because of the limitations of equipment and showed changes suggestive of testicular torsion, as shown in Figures 1 and 2.

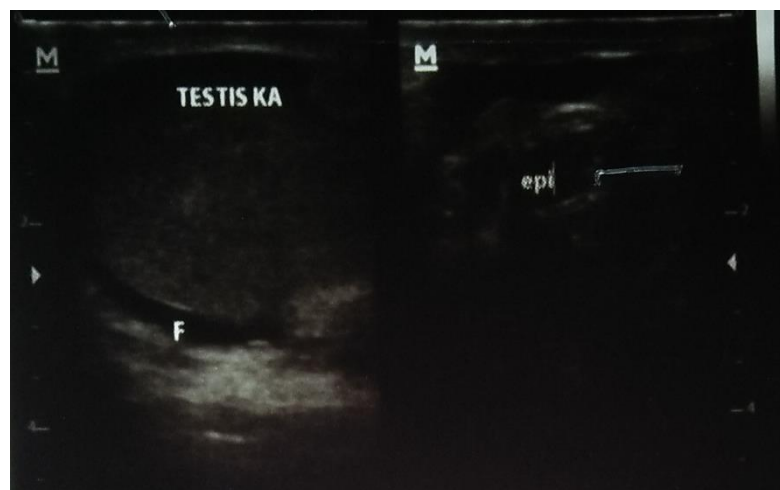


Figure 1. Gray scale ultrasound without Doppler showed on the left: right testicle with reactive hydrocele (F), showed on right: heterogeneous epididymis

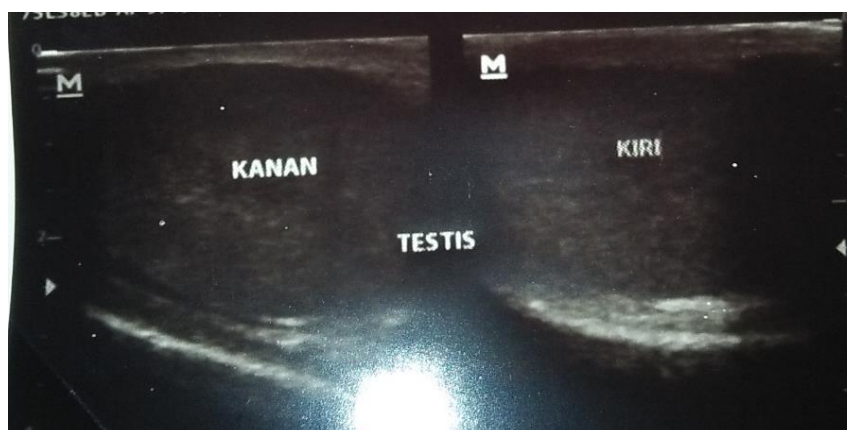


Figure 2. Gray scale ultrasound without Doppler showed on the left: right testicle with heterogenous echogenicity, on the right: left testicle with normal echogenicity

Informed consent was taken then emergency surgery was performed about 8 hours after pain onset. Scrotal exploration revealed a dark-bluish right testicle with a 360° rotation of the spermatic cord, as shown in Figure 3. Detorsion without orchidectomy was performed with the clinical judgment of the attending surgeon hoping for the restoration of testicular viability. Intravenous antibiotic and analgetic were given, that is Cefotaxime 1 gram IV q12h and Ketorolac 30 mg IV q12h for about 2 days. There were no complications after surgery and the patient was discharged from the hospital 2 days later. After 1 week, the surgical wound was cured, postoperative Doppler scrotal ultrasonography was done showing intact good vascularity of right testis with normal echogenicity, horizontal lie, a little remnant of reactive hydrocele, which showed the resolution of testicular torsion as shown in Figure 4 and 5. Sperm analysis was done after one month and oligoasthenoteratozoospermia was found as shown in Table 1.

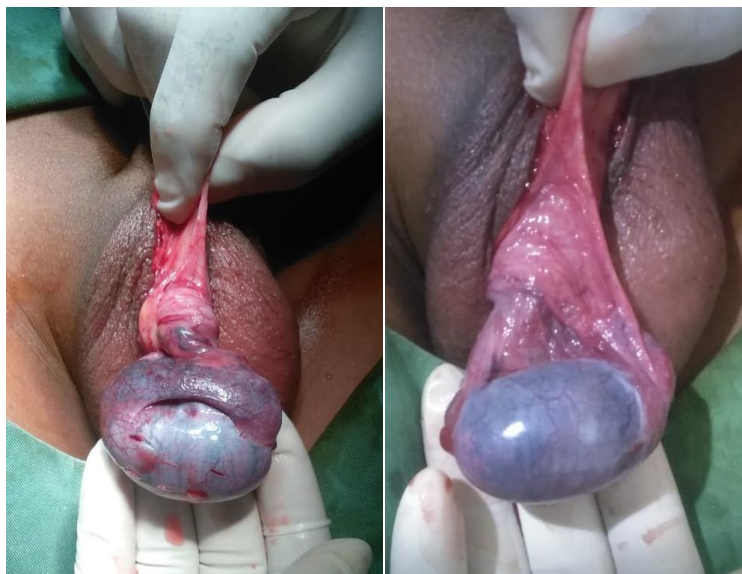


Figure 3. Left picture: Scrotal exploration showed a dark-bluish right testicle with a 360° rotation of the spermatic cord. Right picture: twisted right testicle after a 180° detorsion

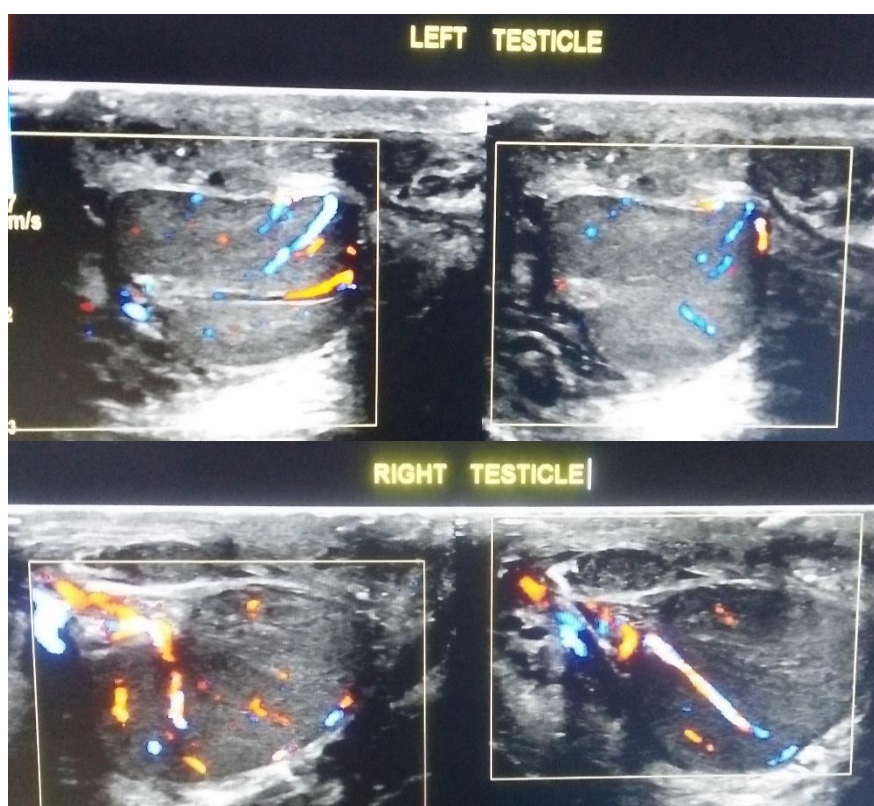


Figure 4. Postoperative Doppler scrotal ultrasonography showing intact vascularity of left testicle (Upper picture) and right testicle (Lower picture).

Table 1. Sperm Analysis result 1 month after the operation

Examination	Result	Reference Value*
Macroscopic		
Volume (mL)	4,2	≥ 2 mL
Smell	Typical	Typical
Color	Grayish white	White or grayish-white
pH	8,1	7,2 – 7,8
Liquefaction (minutes)	55	≤ 60 minutes
Viscosity (cm)	1	≤ 2 cm
Microscopic		
Concentration (10 ⁶ /mL)	10,7	≥ 20 x 10 ⁶ /mL
Count (10 ⁶ /ejaculate)	44,94	≥ 40 x 10 ⁶ /ejaculate
Motility (%)		
1. Progressive (PR)	13	≥ 32%
2. Non-Progressive (NP)	4	%
3. Immotile	83	%
Agglutination	Negative	Negative
Leukocytes (10 ⁶ /mL)	0,4	< 1 x 10 ⁶ /mL
Immature Germ Cell (10 ⁶ /mL)	0,3	x 10 ⁶ /mL
Viability (%)	36	≥ 58%
Morphology (%)		
1. Normal	1	≥ 4%
2. Abnormal	99	%
Diagnosis	Oligoasthenoeratozoospermia	

*Adapted from Cooper TG, Noonan E, von Eckardstein S, Auger J, Baker HWG, Behre HM, et al. World Health Organization reference values for human semen characteristics. Hum Reprod Update. 2009;16(3):231–45.

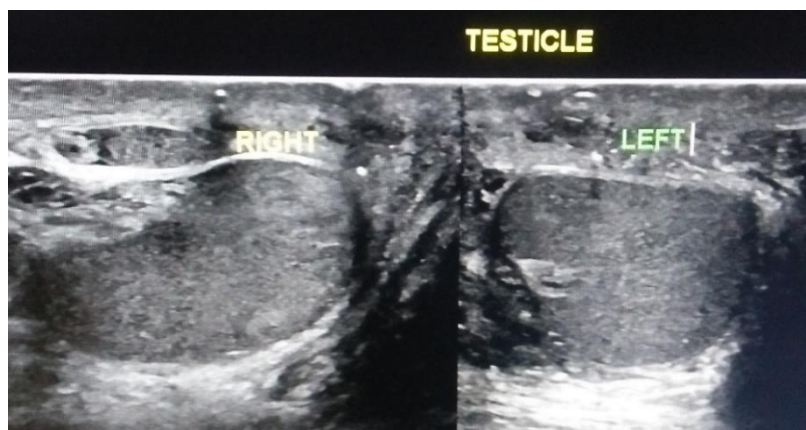

Figure 5. Postoperative scrotal ultrasonography showing normal echogenicity of both testicle

Discussion

Patients with testicular torsion usually complain of acute, severe scrotal pain that occurs at rest (even sleep) or with physical activity, or after trauma. A history of prior episodes may be elicited. Patients may also have inguinal or abdominal pain with milder, less acute, or even absent scrotal pain. Nausea and vomiting occur in 10 – 60% of patients. Scrotal swelling and redness may exist, rely on the degree or duration of torsion. Dysuria and fever are uncommon. The most common physical findings of testicular torsion are generalized testicular tenderness, the abnormal orientation of the testis, and absent cremasteric reflex. The inspection may identify the high-riding testis from a foreshortened cord and horizontally oriented testis.^{2, 8}

Using a standardized history and physical examination form, Srinivasan et al (2011) found that absence of ipsilateral cremasteric reflex, nausea or vomiting, and scrotal skin changes on multivariate analysis were predictive of testicular torsion.⁹ In testicular torsion, color Doppler has a sensitivity ranging from 80 % to 98%, specificity of 97% to 100 %, and an accuracy of 97 %.⁷ Sonographic characteristics most dependable for diagnostic are whirlpool sign of spermatic cord or usually called torsion knot, redundant spermatic cord, horizontal or changed lie, globular testicular enlargement, heterogeneous echotexture, reactive hydrocele, and heterogeneous epididymal enlargement without hyperemia, respectively.^{10, 11}

Detorsion without orchidectomy was performed with the clinical judgment of the attending surgeon hoping for the restoration of testicular viability because of 1) the onset time 8 hours from symptoms until surgical exploration still has a high probability of testicular survival. Even the systematic review performed by Mellick et al (2017) showed that testicular survival is significant even after 24 hours of torsion, with testicular salvage being 90,4% in the first 12 hours after torsion, 54,0% from 13 – 24 hours after torsion, and 18,1% beyond 24 hours survival.¹² (2) there was a case report about testicular torsion patients with a testicle with bluish-black that had improvement of color and showed intact good vascularity after exploration.⁴

There is also a chance that the testicle will experience testicular atrophy despite the factors we described above. Heterogeneous echogenicity that we found on the patient's testicle and epididymis ultrasound are factors that predicted testicular atrophy following testicular salvage in testicular torsion. Moreover, the incidence of testicular atrophy who have undergone salvage surgery in testicular torsion is 54% even when assessed as viable intraoperatively.¹³ While Howe et al (2017) reported a 25% incidence of testicular atrophy after orchiopexy, which proves the reperfusion injury theory had a delayed and lasting impact on testis viability.¹⁴

Sperm analysis was done after one month and oligoasthenoteratozoospermia was found according to WHO reference values for human semen characteristics.¹⁵ This result is similar to researches conducted all over the world. While endocrine function seems unchanged, there is evidence to indicate that TT may adversely affect the fertility of a man evaluated by changes in semen parameters. Thomas et al (1984) evaluated semen quality in 67 patients with TT at a mean follow-up of 4 years after torsion. They discovered that 39 percent had sperm counts below 20 million/mL, so they were graded as subfertile, 64 percent of participants had low sperm morphology or motility, and only 14 percent of participants had normal semen values. Moreover, they discovered that a low total of motile sperm count correlated with the duration of torsion ($p < 0.001$). 55 of the 67 patients included in the research who experienced orchiopexy showing that having a salvageable testis does not put a stop to reduced semen quality in the future.

Arap et al (2007) found that there are no overall differences in semen quality of 24 TT patients with 20 healthy proven fertile men. Yet 25 percent of TT patients had oligospermia when tested individually, compared to 0 percent of men in the control group. Mean sperm counts for patients treated with orchiectomy were 38.3 million/mL ($p = 0.46$) and 47 million/mL for orchiopexy-treated patients ($p = 0.10$) while 99.3 million/mL in the control group.¹ Despite all the findings described above about the negative impact on sperm parameters, interestingly, it seems that there is no impact of the previous TT on pregnancy rates.¹⁶

Gielchinsky et al (2016) evaluated pregnancy rates among 63 couples where the men had experienced TT in the past. When compared to the general population, in TT men, they found no decrease in paternity rates. There is a need for broader cohort studies with long-term follow-up using unselected control groups and explaining potential paternity rates to determine endocrine and exocrine function more clearly after TT.^{1,16} Zhang et al (2020) also conducted a study that investigated the pregnancy rate after testicular torsion. There are 49 patients who had passed through orchiectomy, and 23 had passed through surgical repositioning/orchiopexy. The pregnancy rate and median time to pregnancy were 83.67% (41 from 49) and 1.6 years respectively in the orchiectomy group. While in the repositioning/orchiopexy group, they had been 91.30% (21 from 23) and 0.75 years, respectively. The recent pregnancy rate was higher in patients with a history of childhood torsion than in patients with a history of adolescence torsion. Surgical repositioning/orchiopexy in adolescent torsion patients showed a significantly higher recent pregnancy rate among the three groups, based on age at the time of torsion, and shorter duration to pregnancy than orchiectomy patients.¹⁷

Generally, it looks that some patients experience decreased sperm motility and reduced overall sperm counts at long-term follow-up after TT that perhaps making them subfertile. However, we need more high-quality researches and available studies that are not limited by selection bias. Besides, studies assessing the clinical outcomes of reduced semen quality after TT are still lacking. Because of that, a conclusion on the long-term effects of TT on fertility status cannot be determined.¹

Evidence is contradictory concerning how the affected testicle should be surgically treated. It seems to have a bad impact on testicular function whether to remove the testicle or leave it in the scrotum after detorsion, possibly indicating that bilateral damage is caused by torsion or that the contralateral testis does not have adequate capacity to increase spermatogenesis and testosterone production. Possible contralateral injury after TT is addressed and 3 foremost hypotheses exist as to what might reason the abnormality. 1) Ipsilateral reperfusion damage causes hypoxia by causing contralateral reflective sympathetic induced vasoconstriction causing. 2) The ipsilateral spermatic cord torsion breaks down the blood-testis barrier. This begins an immunological phase in which immunoglobulins have antibody activity in opposition to sperm antigens. In exchange, these immunoglobulins, also known as anti-sperm antibodies (ASA), can decrease the motility and concentration of sperm. 3) Because of pre-existing congenital testicular dysgenesis, the contralateral testicular function is impaired before TT. The majority of cited hypotheses are mainly based on animal studies and low-quality human trials.¹

It is also shown in our case report, where surgical detorsion without orchidectomy as our effort to salvage the torted testicle seems to have a negative effect on testicular function, regardless of the possibility that the testicle is still viable and what is the exact cause. Our case report showed the realistic outcome after testicular torsion despite of the effort to minimize the complication. But, there are limitations on our case report, such as there is not enough case yet to conclude the outcome, and the follow up on sperm analysis is still not enough.

In conclusion, some patients experience decreased of overall sperm parameters after TT that perhaps making them infertile, but the recent studies still show us that there is no difference in pregnancy rates among couples with TT men when compared to the general population. Because of that, it gives the attending doctor information about the patient's chance of having a child in the future. Also, the controversies about performing orchidectomy or orchiopexy alone in terms of salvaging the viable testicle still happen. Many recent studies show that the trial of salvaging the testicle in testicular torsion does not give the best result for preventing testicle atrophy. Because of that, the patient should be carefully counseled about the prognosis, regardless of what is the surgical choice.

Conflict of interest

The authors declared no potential conflicts of interest with respect to the research, authorship, and/or publication of this article. The patient and his parents had received signed informed consent regarding the publication of their respective photograph in the article

Funding Sources

The authors received no financial support for the research, authorship, and/or publication of this article

Acknowledgments

The authors would like to thank all the Hikmah Masamba hospital personnel for their help and support

References

1. Jacobsen, F. M. *et al.* The impact of testicular torsion on testicular function. *World J. Mens. Health* **37**, 1–10 (2019).
2. Sharp, V. J., Kieran, K. & Arlen, A. M. Testicular torsion: Diagnosis, evaluation, and management. *Am. Fam. Physician* **88**, 835–840 (2013).
3. García-Fernández, G., Bravo-Hernández, A. & Bautista-Cruz, R. Testicular torsion: A case report. *Cirugía y Cir. (English Ed.* **85**, 432–435 (2017).
4. T Fawzy, P. A Case with Torsion Testis: Restore Testicular Viability after 18 Hours! *JOJ Urol. Nephrol.* **2**, 2–4 (2017).
5. Kumar, N. & Singh, A. Trends of male factor infertility, an important cause of infertility: A review of literature. *J. Hum. Reprod. Sci.* **8**, 191–196 (2015).
6. Jungwirth, A. *et al.* EAU Guidelines on Male Infertility 2018. *Eur. Assoc. Urol. Guidel. 2018 Ed.* 6–7 (2018).
7. Soumya J, Phatak SV, Varma A, M. G. Testicular torsion – USG and Color Doppler correlation: A case report. *Med. Sci.* **24**, (2020).
8. Palmer LS, P. J. *Campbell-Walsh-Wein Urology Twelfth Edition.* (Elsevier Ltd, 2020).
9. Srinivasan, A., Cinman, N., Feber, K. M., Gitlin, J. & Palmer, L. S. History and physical examination findings predictive of testicular torsion: An attempt to promote clinical diagnosis by house staff. *J. Pediatr. Urol.* **7**, 470–474 (2011).
10. Bandarkar, A. N. & Blask, A. R. Testicular torsion with preserved flow: key sonographic features and value-added approach to diagnosis. *Pediatr. Radiol.* **48**, 735–744 (2018).
11. Wu, S., Liu, G., Chen, S. & Guan, Y. Sonographic patterns of testicular torsion. *J. Diagnostic Med. Sonogr.* **27**, 273–278 (2011).
12. Mellick, L. B., Sinex, J. E., Gibson, R. W. & Mears, K. A Systematic Review of Testicle Survival Time after a Torsion Event. *Pediatr. Emerg. Care* **35**, 821–825 (2019).
13. Lian, B. S. Y., Ong, C. C. P., Chiang, L. W., Rai, R. & Nah, S. A. Factors Predicting Testicular Atrophy after Testicular Salvage following Torsion. *Eur. J. Pediatr. Surg.* **26**, 17–21 (2015).
14. Howe, A. S. *et al.* Degree of twisting and duration of symptoms are prognostic factors of testis salvage during episodes of testicular torsion. *Transl. Androl. Urol.* **6**, 1159–1166 (2017).
15. Cooper, T. G. *et al.* World Health Organization reference values for human semen characteristics. *Hum. Reprod. Update* **16**, 231–245 (2009)
16. Gielchinsky, I. *et al.* Pregnancy Rates after Testicular Torsion. *J. Urol.* **196**, 852–855 (2016).
17. Zhang, X. *et al.* Effect of unilateral testicular torsion at different ages on male fertility. *J. Int. Med. Res.* **48**, (2020).